

Principles of Reconstructive Surgery in Degenerative Mitral Valve Disease

Farzan Filsoufi, MD,* and Alain Carpentier, MD, PhD[†]

Degenerative mitral valve disease is the most common cause of mitral regurgitation (MR) in developed countries. The most common etiologies of valvular regurgitation are Barlow's disease and fibroelastic deficiency. The mechanism of MR is type II dysfunction (leaflet prolapse) due to chordae elongation or rupture in most patients. Associated annular dilation is a common lesion in almost all patients with chronic MR. By means of segmental valve analysis, isolated posterior leaflet prolapse (P2 segment) is often observed in patients with fibroelastic deficiency, whereas the prolapse of multiple segments or bileaflet prolapse is typically seen in patients with Barlow's disease. In patients with degenerative mitral valve disease and severe MR, reconstructive surgery should be performed before the occurrence of clinical symptoms, atrial fibrillation, pulmonary hypertension, and left ventricular dysfunction or enlargement. The goals of reconstructive surgery are preservation or restoration of normal leaflet motion, creation of a large surface of coaptation, and stabilization of the entire annulus with a remodeling annuloplasty. Today, reconstructive techniques are standardized, reliable, and reproducible, and therefore should be applied systematically to all patients with degenerative valvular disease.

Semin Thorac Cardiovasc Surg 19:103-110. © 2007 Published by Elsevier Inc.

KEYWORDS degenerative mitral valve disease, mitral regurgitation, Carpentier's reconstructive techniques

Degenerative mitral valve disease is the most common cause of mitral regurgitation (MR) in developed countries. Several confusing terminologies (eg, myxomatous valve disease, mitral valve prolapse, floppy valve, flail leaflet) have been used in the literature to describe degenerative mitral valve disease. The understanding of valve pathology is facilitated by the use of the "pathophysiological triad."¹

Pathophysiology and Functional Classification

The pathophysiologic triad is composed of etiology (cause of the disease), valve lesions (resulting from the disease), and valve dysfunction (resulting from the lesion).¹ These distinctions are relevant because long-term prognosis depends on

etiology, whereas treatment strategy and surgical techniques depend on valve dysfunctions and lesions, respectively.

Carpentier's functional classification is used to describe the mechanism of mitral regurgitation (Fig. 1).¹ This classification is based on the opening and closing motions of the mitral leaflets. Patients with type I dysfunction have normal leaflet motion. Mitral regurgitation in these patients is due to annular dilation or leaflet perforation. There is an increased leaflet motion in patients with type II dysfunction, with the free edge of the leaflet overriding the plane of the annulus during systole (leaflet prolapse). The most common lesions responsible for type II dysfunction are chordae elongation or rupture and papillary muscle elongation or rupture. Patients with type IIIa dysfunction have a restricted leaflet motion during both diastole and systole. The most common lesions are leaflet thickening and retraction, chordae thickening and shortening or fusion, and commissural fusion. MR is most often associated with some degrees of mitral stenosis. The mechanism of MR in type IIIb dysfunction is restricted leaflet motion during systole. Left ventricular enlargement with apical papillary muscle displacement causes this type of valve dysfunction.

The functional classification is further refined by the intro-

*Department of Cardiothoracic Surgery, Mount Sinai School of Medicine, New York, New York.

[†]Hospital European Georges-Pompidou, Paris, France.

Address reprint requests to Farzan Filsoufi, MD, Associate Professor, Associate Chief Cardiac Surgery, Department of Cardiothoracic Surgery, Mount Sinai Hospital, 1190 Fifth Avenue, Box 1028, New York, NY 10029-1028. E-mail: farzan.filsoufi@mountsinai.org

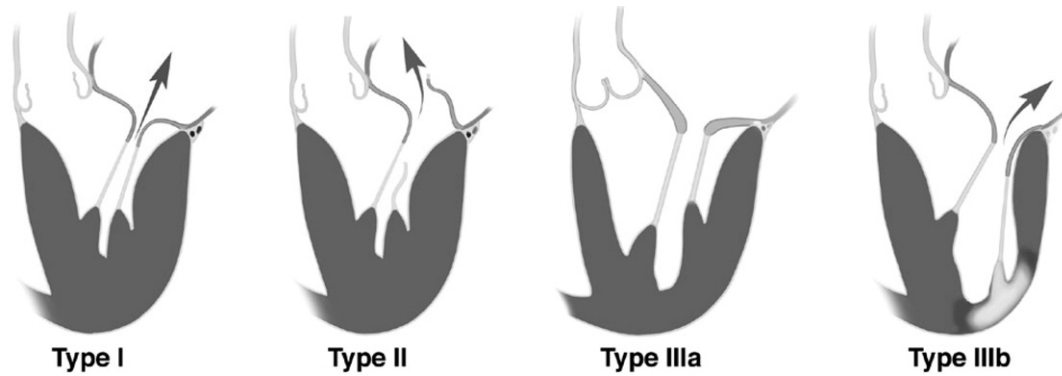


Figure 1 Carpentier's functional classification.

duction of segmental analysis, which allows the precise localization of leaflet dysfunction; this is of critical importance while performing reconstructive surgery.²

The mitral valve is separated into 8 segments (Fig. 2). Anterolateral and posteromedial commissures are 2 segments. Two indentations on the posterior leaflet divide this structure into 3 anatomically individualized scallops. The 3 scallops of the posterior leaflet are identified as P1 (anterior scallop), P2 (middle scallop), and P3 (posterior scallop). The 3 corresponding segments of the anterior leaflet are A1 (anterior segment), A2 (middle segment), and A3 (posterior segment).

Application of Pathophysiologic Triad in Patients with Degenerative Mitral Valve Disease

Etiologies of degenerative mitral disease include Barlow's disease, Marfan's disease, and fibroelastic deficiency. The mechanism of MR is often leaflet prolapse (type II dysfunction) due

to chordae rupture or elongation. Barlow's disease is the most common condition, affecting up to 3% of the population, whereas fibroelastic deficiency is observed with increasing frequency as the age of the population increases.

Barlow's disease appears early in life, and patients typically have a long history of a systolic murmur.^{3,4} Most patients who require surgery for MR are referred for surgery in their fourth or fifth decades of life. The valve is billowing with typically thick leaflets and with marked excess tissue. The chordae are thickened and elongated, and may be ruptured. Papillary muscles are also occasionally elongated. The annulus is dilated and sometimes calcified. Most Barlow's valves present with the prolapse of multiple segments of the valve. Bileaflet prolapse is present in about 30% of patients. Histologically, there is extensive myxoid degeneration with destruction of the normal 3-layer leaflet tissue architecture.

Fibroelastic deficiency is most common in elderly patients (>65 years) with a relatively short history of mitral regurgitation.⁴ Valve analysis typically shows transparent leaflets with no excess tissue except in the prolapsing segment, and elongated, thin, frail, and often ruptured chordae. The annulus is often dilated and may be calcified. Most of these patients present with isolated P2 prolapse.

Marfan's disease with mitral regurgitation is characterized by excess leaflet tissue, which may be thickened (without myxoid degeneration), and a dilated annulus that is rarely calcified.⁵

Principles of Mitral Valve Surgery

Perioperative Management

Standard techniques of monitoring (eg, arterial line, central venous access, Foley catheter) are used in patients undergoing mitral valve reconstructive surgery. A Swan-Ganz catheter should be placed in cases of complex mitral valve reconstructive surgery, multivalve surgery, combined mitral and coronary artery bypass grafting surgery, and in patients with increased operative risk (eg, left ventricular dysfunction, pulmonary hypertension, reoperation). Initially, a transesophageal echocardiography (TEE) should be performed in all pa-

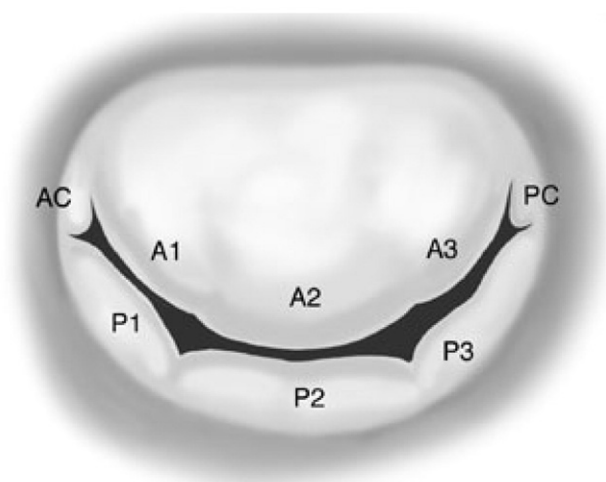


Figure 2 Segmental valve analysis.

tients. TEE is important to determine the mechanism and severity of mitral regurgitation, and to assess left ventricular function, quality of reconstruction, and de-airing of the cardiac cavities at the completion of the procedure. An external defibrillator is placed in reoperation and in minimally invasive approaches. A double-lumen endotracheal tube is necessary in right thoracotomy incisions.⁶ An epi-aortic scanning of the ascending aorta is recommended in elderly patients with associated atherosclerotic risk factors, and those undergoing a combined mitral valve and coronary artery bypass grafting surgery before arterial cannulation.

Surgical Incisions and Cardiopulmonary Bypass

A small skin incision and a midline sternotomy is our favorite surgical approach in mitral valve reconstructive surgery. It provides an excellent access to all cardiac structures, which allows for central cannulation with the ascending aorta and the superior and inferior vena cava.

Mini-invasive direct vision mitral surgery is performed through the partial upper or lower hemisternotomy. A 6-cm skin incision is performed in both cases. The sternum is partially divided from the sternal notch to the left fourth intercostal space (upper hemisternotomy) and from the xyphoid to the second right intercostal space (lower hemisternotomy).⁷ Central arterial and venous cannulations are often possible with these approaches. Video-directed⁸ and robotic mitral valve surgeries are performed through a right mini-thoracotomy at the fourth intercostal space. Multiport access is obtained by additional keyhole incisions. Peripheral vessels are used to initiate cardiopulmonary bypass. Additional adjunctive techniques such as port access instrumentation, carbon dioxide insufflation, and vacuum-assisted venous drainage are commonly used to facilitate these surgical procedures.

Myocardial protection is achieved with intermittent antegrade or a combined antegrade and retrograde infusion of high-potassium, cold-blood cardioplegia. Further myocardial protection can be obtained by moderate systemic hypothermia between 28°C and 30°C. The myocardial temperature should be assessed continuously throughout the procedure and maintained below 15°C. If it exceeds 15°C, additional administration of cardioplegic solution is required.

Mitral Valve Exposure and Intraoperative Valve Analysis

Perfect exposition of the mitral valve is essential before undertaking mitral valve reconstructive surgery. We favor the interatrial approach through the Sondergaard's groove. The interatrial groove is incised, and the 2 atria are dissected and divided up to the fossa ovalis. This dissection exposes the roof of the left atrium, which is opened close to the mitral valve.² In patients with a small left atrium, the inferior extension of the left atrial incision between the right inferior pulmonary vein and inferior vena cava optimizes the mitral valve exposure.

The entire mitral valve apparatus must be carefully examined to confirm the mechanism of mitral regurgitation, to assess the feasibility of reconstruction, and to plan the exact operative strategy. The endocardium of the left atrium is examined for jet lesions, which indicate opposite leaflet prolapse. The mitral annulus is examined to assess the severity of annular dilation, and the presence and extent of calcification. The valvular apparatus is examined with a nerve hook to assess the severity and extent of leaflet prolapse according to segmental valve analysis.² The anterior paracommissural scallop of the posterior leaflet (P1) is often intact and rarely prolapsing in patients with degenerative disease. The P1 segment constitutes the reference point.¹ Applying traction to the free edge of other valvular segments and comparing them with P1 determines the severity and extent of leaflet prolapse.

Fundamentals of Mitral Valve Reconstructive Surgery

The goals of reconstructive surgery are preservation or restoration of normal leaflet motion, creation of a large surface of coaptation, and stabilization of the entire annulus with a remodeling annuloplasty.¹ Current surgical techniques allow surgeons to perform reconstructive surgery in almost all patients with degenerative mitral disease, provided that these guidelines are followed carefully.

Posterior Leaflet Prolapse

Posterior leaflet prolapse is treated by a quadrangular resection of the prolapsed area. Stay sutures are placed around the normal chordae to determine the prolapsed area. The prolapsed segment is then removed by performing a perpendicular incision from the free edge toward the annulus, resecting a quadrangular portion of the leaflet. Plication sutures are placed along the posterior annulus in the resected area. Finally, direct sutures of the leaflet remnants restore valve continuity without tension (Fig. 3).

When excessive posterior leaflet tissue is present, such as in Barlow's disease, it is important to reduce the height of the posterior leaflet to less than 15 mm to prevent postoperative systolic anterior motion (SAM).⁹ A sliding leaflet technique is performed after quadrangular resection. The P1 and P3 segments are detached from the annulus; compression sutures are then placed in the posterior segment of the annulus. A sliding plasty of the P1 and P3 segments is performed, and the gap between the 2 scallops is closed with interrupted sutures (Fig. 4). In Barlow's valve with significant excess tissue of posterior leaflet, an additional triangular resection at the base of P1 and P3 may be necessary before proceeding with the sliding leaflet plasty.

Sliding plasty is also indicated if a large segment of the posterior leaflet is resected. Plication of a large segment of the posterior annulus must be avoided because of the increased risk of circumflex artery kinking.

Anterior Leaflet Prolapse

Several techniques are available to correct anterior leaflet prolapse depending on the extent of the prolapse and the lesions responsible (chordae elongation vs rupture).

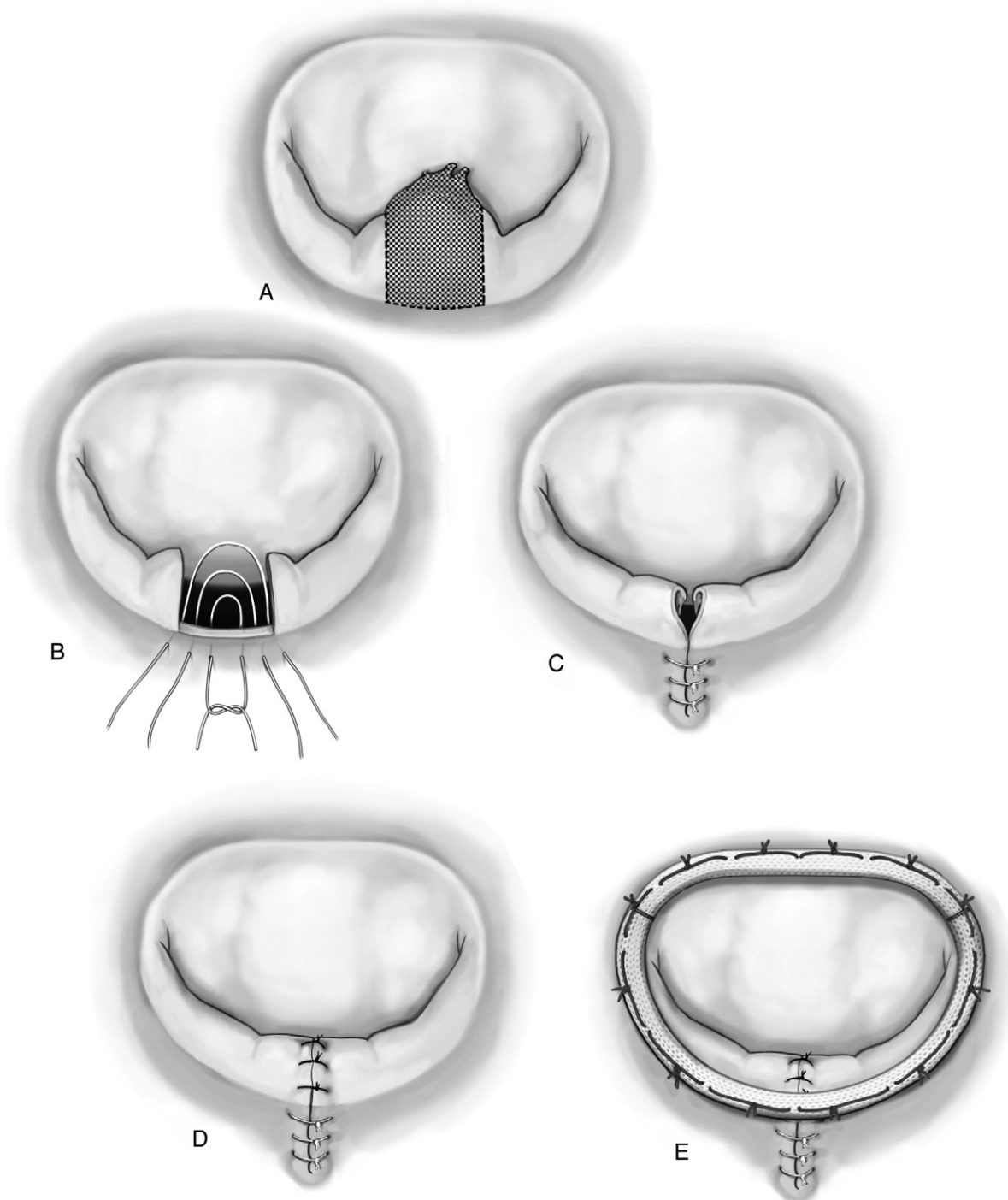


Figure 3 Posterior leaflet quadrangular resection with annular plication.

Triangular Resection. Limited prolapse of the anterior leaflet with excess tissue can be treated by a small, triangular resection of the prolapsed area followed by direct closure with interrupted monofilament sutures. The triangular resection must not be extended to the body of the anterior leaflet and should not involve more than 10% of the anterior leaflet surface area. Large resection of the anterior leaflet distorts the geometry and reduces the coaptation area. In addition, it compromises leaflet mobil-

ity considerably and is incriminated as a risk factor for repair failure.

Chordae Transposition. Chordae transposition from the secondary position to the free margin of the anterior leaflet is the most preferable technique. A strong and normal secondary chordae adjacent to the prolapsing area is identified. This chordae is detached at 2 mm from its origin on the body of the anterior leaflet. If the chordae is cut at its base, this will

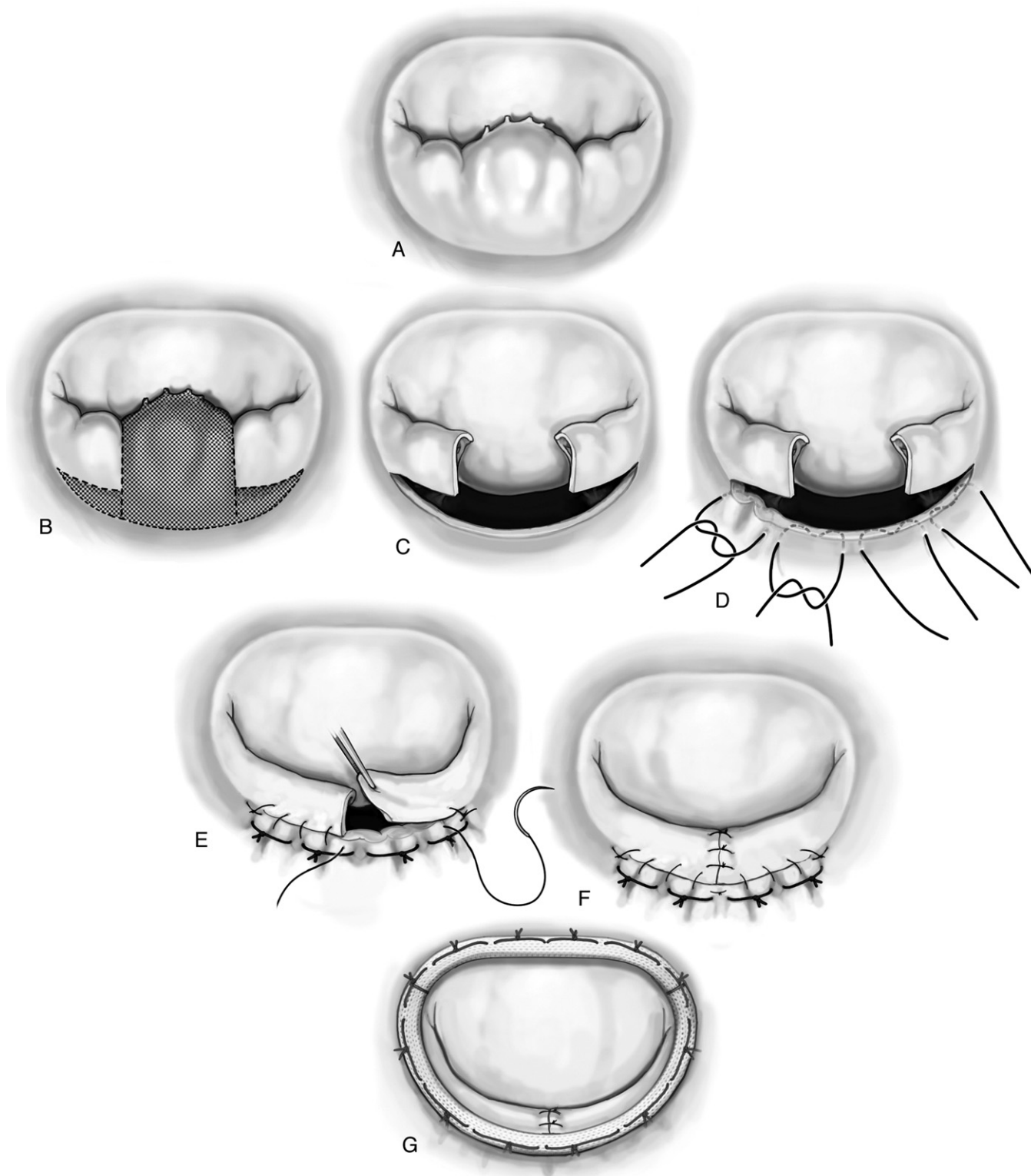


Figure 4 Posterior leaflet quadrangular resection with sliding leaflet plasty.

likely cause leaflet perforation. It is then attached to the free margin of the anterior leaflet in the prolapsed area with a figure-of-8 suture. In case of a large prolapsed area, several secondary chordae should be transferred to the free margin with a maximum 5-mm interval between 2 adjacent chordae.

In the absence of normal secondary chordae, chordae

transposition from the posterior leaflet to the anterior leaflet should be considered. If marginal chordae of the posterior segment opposite to the prolapsed area of the anterior leaflet is normal, it can be used for chordae transposition. A small segment of the posterior leaflet with its marginal chordae is detached and then reattached to the free margin of the ante-

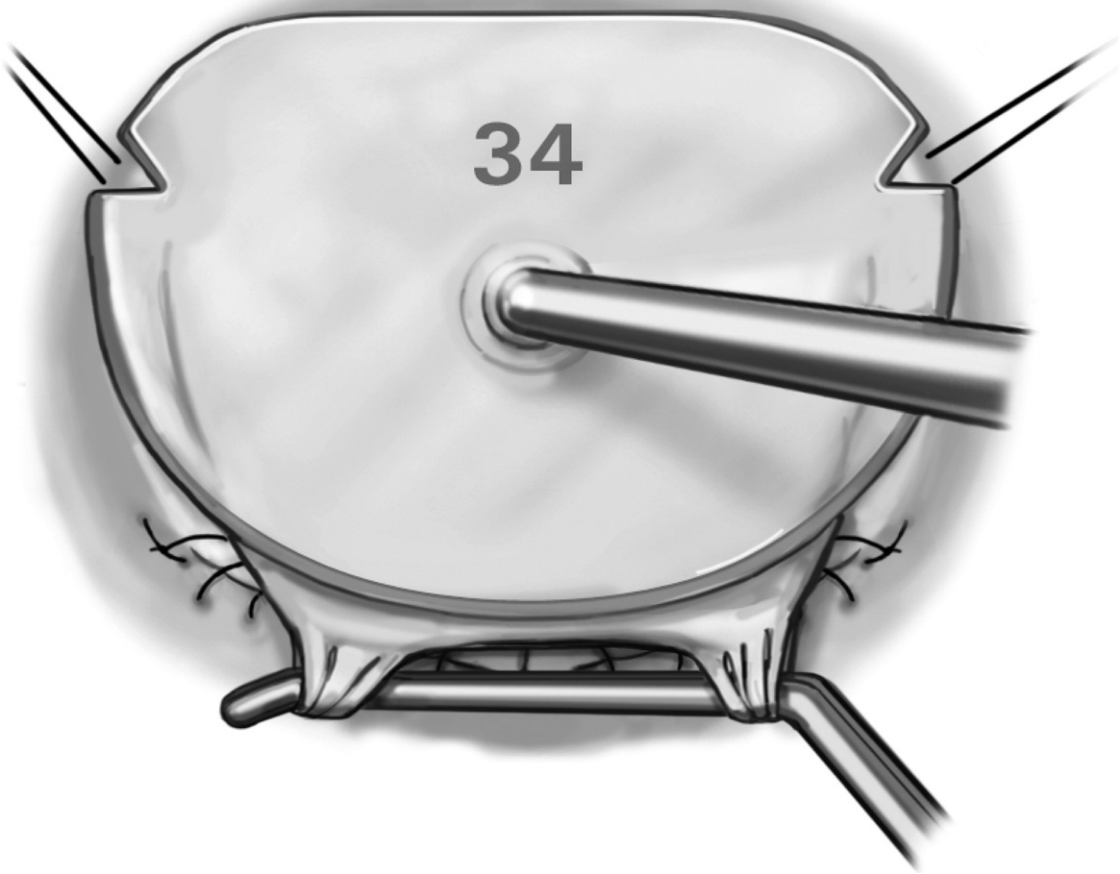


Figure 5 Ring selection based on sizing of the mitral valve: (1) measure of intercommissural distance; (2) measure of the anterior leaflet surface area.

rior leaflet at the site of prolapse. Interrupted sutures are used to close the defect in the posterior leaflet.

If these 2 techniques cannot be applied, the use of artificial chordae is a valuable alternative.

Papillary Muscle Sliding Plasty. This technique is convenient for anterior leaflet prolapse due to elongation (<5 mm) of multiple chordae arising from a papillary muscle. The portion of the papillary muscle supporting the elongated chordae is split longitudinally and resutured to the other portion at a lower level. This downward displacement of papillary muscle corrects leaflet prolapse.

Papillary Muscle Shortening. Papillary muscle elongation or chordae elongation involving a group of chordae can also be treated by papillary muscle shortening. A triangular wedge at the base of the papillary muscle is resected. This defect is then closed by direct suture resulting in a reduced height of the papillary muscle and correction of chordae length. Papillary muscle shortening not only corrects the leaflet prolapse but also reduces considerably the billowing of the leaflet body. This procedure is typically indicated in Barlow's disease with bileaflet prolapse.

Commissural Prolapse

Commissural prolapse is best treated by resection of the prolapsed area followed by annular plication (limited prolapse) or sliding plasty of the paracommissural area (extensive prolapse) (eg, A1 and P1 sliding plasty for anterolateral commissural prolapse). Additional inverting sutures should be placed in the newly created commissure to avoid residual minimal regurgitation. Occasionally, a patient can present with a papillary muscle with 2 heads. The rupture of 1 head can lead to commissural prolapse, which can be corrected by reattachment of the latter to the remnant papillary muscle. If extensive commissural and paracommissural prolapse due to chordae elongation are present, papillary muscle sliding plasty or papillary muscle shortening are valuable alternative options.

Remodeling Ring Annuloplasty

In patients with a normal mitral valve, the ratio between anteroposterior (septolateral) and transverse diameter of the mitral annulus is 3:4 during systole. This ratio is inverted in patients with degenerative mitral valve disease and annular dilation.¹ The remodeling ring annuloplasty restores the physiologic ratio with maximal orifice area during systole.

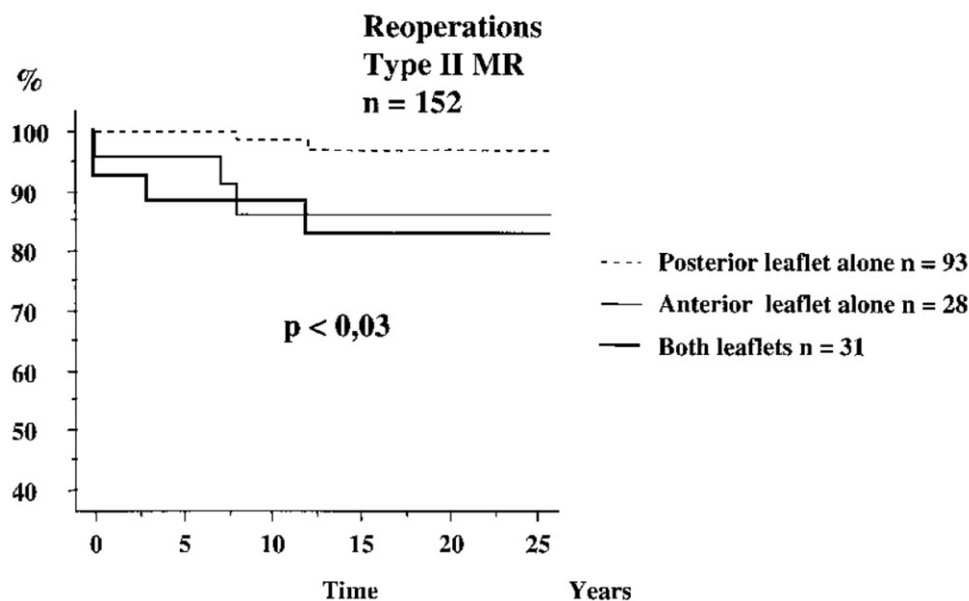


Figure 6 Reoperation according to leaflet prolapse.

Therefore, the prosthetic ring restores not only the size but also the shape of the annulus. Remodeling annuloplasty provides increased leaflet coaptation area without causing any valvular stenosis. Furthermore, it prevents late annular dilation and preserves leaflet mobility. Appropriate ring sizing is based on the intercommissural distance and the surface area of the anterior leaflet, measured with an obturator (Fig. 5). If the surgeon hesitates between 2 sizes, in patients with degenerative valve disease, the selection of the greater size is recommended in most instances.² In Barlow's valve, the typical size of the prosthetic ring is between 36 and 40 mm.¹⁰ The choice of too small a ring increases significantly the risk of postrepair SAM.¹¹

Sutures are placed circumferentially through the mitral annulus. These sutures are equally spaced in the area between the 2 commissures and the corresponding segment of the selected prosthetic ring. In the remaining portion of the annulus, the spacing is set to conform the annulus to the shape and size of the prosthetic ring. When the ring sutures are tied, the ring reshapes the annulus in its normal systolic position.

Saline Test and Postbypass TEE

The quality of the repair must be evaluated at the completion of the reconstruction and before tying the ring to the annulus with a saline test. Saline solution is injected into the ventricular cavity through the mitral valve with a syringe, while the aortic root is vented to prevent air emboli into the coronary arteries. A symmetric line of coaptation, parallel to the posterior aspect of the annulus, and at distance from the left ventricular outflow tract (3/4 to 1/4 ratio of anterior to posterior leaflet) indicates a satisfactory result. An asymmetrical line of coaptation indicates the presence of residual leaflet prolapse or restricted leaflet motion, which must be corrected. If the posterior leaflet occupies half or more of the orifice area, its height should be reduced (less than 15 mm) to

minimize the risk of SAM. Two hooks should also be used to determine the length of the coaptation, which is ideally more than 10 mm. At the completion of cardiopulmonary bypass, the quality of reconstruction is assessed by TEE. This examination should carefully evaluate leaflet motion and the competency of the valve, and rule out the presence of postvalvuloplasty SAM in patients with excess leaflet tissue. In the presence of residual regurgitation, TEE is crucial to determine the severity and the mechanism of regurgitation, which may justify a second look. No patient should leave the operating room with more than 1+ residual MR. In patients with $\geq 2+$ MR, a second bypass run is necessary to reanalyze the valve and correct a residual valvular dysfunction.

Results

Patients with degenerative mitral valve disease are the most suitable for reconstructive surgery. The operative mortality rate in this group of patients is less than 0.5% in experienced centers.¹⁰ In patients with severe MR, reconstructive surgery should be performed before the occurrence of clinical symptoms, atrial fibrillation, pulmonary hypertension, and left ventricular dysfunction or enlargement.

The long-term survival of patients with preserved left ventricular function after reconstructive surgery is similar to that of an age- and gender-matched population.

Our group has recently published the very long-term results (>20 years) of mitral reconstructive surgery.¹² This observational study of 162 consecutive patients operated on between 1970 and 1984 was mostly composed of patients with degenerative disease (90%). The main mechanism of mitral regurgitation was type II dysfunction in 152 (94%) patients. Posterior, anterior, and bileaflet prolapse were present in 93 (61%), 28 (19%), and 31 (20%) patients, respectively. All patients underwent annuloplasty; valve resec-

tion was performed in 126 patients, and shortening or transposition of the chordae in 46 patients. The linearized rate of reoperation was 0.4% per patient year. Freedom from reoperation was 97%, 86%, and 83% for posterior, anterior, and bileaflet prolapse, respectively, at 20 years (Fig. 6). The increased rate of early reoperation in the anterior leaflet prolapse group was attributed to technical failure. The widespread use of intraoperative TEE and improved surgical techniques (chordae transfer) has most likely contributed to reducing the incidence of early failure in the last 2 decades. However, the freedom from reoperation was unchanged at 10, 20, and 25 years of follow-up. These excellent and stable results confirm the predictability and durability of mitral valve reconstruction in degenerative disease. Today, reconstructive valve surgery allows patients to enjoy a normal life and to be cured for the rest of their lives.

References

1. Carpentier A: Cardiac valve surgery—the “French correction.” *J Thorac Cardiovasc Surg* 86:323-337, 1983
2. Carpentier AF, Lessana A, Relland JY, et al: The “physio-ring”: an advanced concept in mitral valve annuloplasty. *Ann Thorac Surg* 60: 1177-1186, 1995
3. Barlow JB, Bosman CK, Pocock WA, et al: Late systolic murmurs and non-ejection (“mid-late”) systolic clicks. An analysis of 90 patients. *Br Heart J* 30:203-218, 1968
4. Carpentier A, Chauvaud S, Fabiani JN, et al: Reconstructive surgery of mitral valve incompetence: ten-year appraisal. *J Thorac Cardiovasc Surg* 79:338-348, 1980
5. Fuzellier JF, Chauvaud SM, Fornes P, et al: Surgical management of mitral regurgitation associated with Marfan’s syndrome. *Ann Thorac Surg* 66:68-72, 1998
6. Adams DH, Filsoufi F, Byrne JG, et al: Mitral valve repair in redo cardiac surgery. *J Card Surg* 17:40-45, 2002
7. Loulmet DF, Carpentier A, Cho PW, et al: Less invasive techniques for mitral valve surgery. *J Thorac Cardiovasc Surg* 115:772-779, 1998
8. Casselman FP, Van Slycke S, Dom H, et al: Endoscopic mitral valve repair: feasible, reproducible, and durable. *J Thorac Cardiovasc Surg* 125:273-282, 2003
9. Jebara VA, Mihaileanu S, Acar C, et al: Left ventricular outflow tract obstruction after mitral valve repair. Results of the sliding leaflet technique. *Circulation* 88:II30-34, 1993
10. Adams DH, Anyanwu AC, Rahmanian PB, et al: Large annuloplasty rings facilitate mitral valve repair in Barlow’s disease. *Ann Thorac Surg* 82:2096-2101, 2006
11. Mihaileanu S: Outflow tract obstruction and failed mitral repair. *Circulation* 90:1107-1108, 1994
12. Braunberger E, Deloche A, Berrebi A, et al: Very long-term results (more than 20 years) of valve repair with carpentier’s techniques in nonrheumatic mitral valve insufficiency. *Circulation* 104:18-11, 2001 (suppl 1)